



OPTIMIZATION OF EXERCISE THERAPY TO INCREASE THORACIC CAGE EXPANSION IN TUBERCULOUS MENINGITIS CASES

Ahmad Akbar Pamungkas 1^{*}, Amalga Tri Gusta Nanda 2² Dinda Dwi Anggari, 3³, Enitha Gamganora 4⁴, Isna Rahma 5⁵, Arshy Prodyanatasari 6⁶, Whida Rahmawati 7⁷
¹D3 Physiotherapy, Bhakti Wiyata Institute of Health Sciences Kediri, Indonesia

Email: ¹ ahmadakbar.p115@gmail.com

^{*} Corresponding Author

Received: 30 September 2025

Revised: 01 October 2025

Accepted: 02 October 2025

Published online:

Abstract

Tuberculous meningitis (TBM) is the most severe form of tuberculosis, causing significant neurological impairment and respiratory complications in children. The novelty of this research (a) lies in demonstrating the application of a simple, practical physiotherapy protocol within a resource-limited healthcare setting. The objective of this study (b) is to report the effectiveness of this physiotherapy intervention for a 9-year-old boy with TBM. The methods employed (c) included a series of interventions over three sessions, comprising positioning to optimize ventilation and prevent pressure sores, passive breathing exercises to support lung capacity, and passive mobilization to maintain joint range of motion and control spasticity. Evaluation was based on thoracic expansion measurements, the Glasgow Coma Scale (GCS), and spasticity assessment. The empirical results (d) indicated notable clinical improvements, including increased thoracic expansion, enhanced level of consciousness, and stabilized spasticity. The study's implications (e) confirm that a consistent regimen of straightforward physiotherapy techniques can significantly support the recovery process of pediatric TBM patients, offering a viable and accessible supportive care model for hospitals with constrained resources.

Keywords:

Passive breathing exercise, passive mobilization, physiotherapy, positioning, tuberculous meningitis

INTRODUCTION

Tuberculosis (TB) is an infectious disease that remains a global health challenge, especially in developing countries with limited access to health services, high poverty rates, and poor nutrition. (Global Tuberculosis Report, 2023). The pathogenesis of TBM begins with the inhalation of droplets containing *M. tuberculosis* bacilli. After reaching the lungs, the bacteria can spread through the bloodstream (hematogenous) to other organs, including the brain. In the brain, the bacteria infect microglia cells and penetrate the blood-brain barrier, forming granulomas known as Rich foci. The rupture of these foci into the subarachnoid space causes meningeal inflammation, the formation of thick exudate, and the spread of infection in the cerebrospinal fluid (Manyelo et al., 2021). Tuberculous meningitis (MTB) is the most dangerous *Mycobacterium tuberculosis* infection and is a medical emergency. Patients with MTB infection who survive are likely to experience neurological deficits or permanent sequelae. Diagnosis of MTB is often delayed or inaccurate because the clinical manifestations of MTB patients vary from acute meningitis syndrome to progressive dementia. Detecting *Mycobacterium tuberculosis* complex bacteria from cerebrospinal fluid remains a challenge due to low sensitivity rates. Bacteriological diagnosis is difficult due to the paucibacillary nature of the bacteria and the difficult and invasive specimen collection process (Thuong et al., 2017).

Tuberculous meningitis (TB) occurs due to the entry of *Mycobacterium tuberculosis* bacteria into the cerebrospinal fluid (CSF) through bacteremia originating from a focal infection in the lungs. However, this study shows that nearly half (47.1%) of patients do not have pulmonary TB, so the spread can also occur from other organs. TB meningitis is often found in individuals with immunocompromised conditions, such as patients with HIV/AIDS or low CD4 counts, as well as in young and elderly individuals. This condition causes the body to be unable to resist the spread of bacteria, allowing the infection to reach the central nervous system. Inflammation of the meninges is characterized by basal meningeal enhancement, infarction, or hydrocephalus on CT scan (Catur Bintoro et al., 2013). According to the WHO, approximately 10.6 million people worldwide were infected with TB in 2021, with 1.6 million people dying from TB. Most TB cases are in developing countries, one of which is Indonesia (Global Tuberculosis Report, 2022). Then in 2022, according to the Global Tuberculosis Report 2022, Indonesia ranked second with the highest number of tuberculosis patients in the world, with an estimated 969,000 cases. Tuberculosis is an infection caused by the *M. Tuberculosis* bacteria, which most often attacks the lungs (Global Tuberculosis Report, 2022). BCG immunization status was significantly associated with severity ($p=0.046$) and mortality ($p=0.047$) in children with TB meningitis, with unvaccinated children having a higher risk of severe disease and death (Poety Elberta Husna Nixon, 2025).

BCG vaccination has been proven effective in reducing the risk of severe tuberculosis, including tuberculosis meningitis in children, with significant protection against mortality and long-term complications (Liao et al., 2022). To address this issue, faster and more accurate diagnostic methods and effective treatment strategies are needed so that patients can receive timely therapy. This comprehensive approach is expected to increase recovery rates, reduce mortality rates, and reduce the risk of long-term complications. Understanding the basic elements of TB meningitis, including the disease mechanism, risk factors, symptoms, and management techniques, is an important step in prevention, early detection, and optimal treatment (Global Tuberculosis Report, 2021).

Several previous studies have highlighted the importance of physiotherapy intervention in patients with tuberculous meningitis. Physiotherapy intervention is a series of planned and systematic actions provided by physiotherapists to maintain, restore, or improve the patient's bodily

functions, as well as prevent complications resulting from prolonged immobilization. One form of intervention that is often used is exercise therapy, which is a therapeutic method that involves structured body movements and aims to increase muscle strength, maintain joint mobility, reduce pain, and improve respiratory function (Pakhan & Raghumahanti, 2024a). Reporting that an intensive six-week physiotherapy program can reduce spasticity, prevent joint stiffness, and improve patients' functional independence. In addition, (Aherrao et al., 2024a) Explaining that passive and active range of motion (ROM) exercises are effective for maintaining joint mobility and preventing contractures in patients with neurological disorders due to prolonged immobilization. Interventions such as passive breathing exercises, as described by [author], explain that passive and active range of motion (ROM) exercises are effective in maintaining joint mobility and preventing contractures in patients with neurological disorders resulting from prolonged immobilization. Interventions such as passive breathing exercises, as described by (Kisner & Colby, 2022), also plays an important role in improving lung expansion and respiratory capacity, which is very beneficial for TB meningitis patients with respiratory disorders. Physiotherapy for chronic lung disease has generally been proven to provide significant benefits. According to (Garrod & Lasserson, 2007), Respiratory physiotherapy can reduce respiratory effort, improve ventilation, improve sputum clearance, and support the quality of life of patients with chronic respiratory diseases. This is in line with the objectives of intervention in TBM patients, namely to maintain basic bodily functions, improve lung capacity, and prevent long-term complications.

The synthesis of this study shows that a comprehensive physiotherapy approach, including passive mobilization, breathing exercises, and proper positioning, has a significant impact on supporting patient recovery, maintaining basic bodily functions, and preventing further complications. The objective of this study was to assess the effectiveness of physiotherapy through passive mobilization, breathing exercises, and positioning in improving thoracic expansion, basic bodily functions, and the consciousness of MTB patients. The novelty of this study lies in the application of a simple intervention that has been proven to provide significant improvement in three sessions and can be used as a practical reference in facilities with limited resources (Aherrao et al., 2024b).

METHODS

This study is a mixed-method study using a case study method conducted at the RSUD Haji Provinsi Jawa Timur from December 2024 to March 2025. The subjects of this study were patients who met the inclusion criteria, including age ≤ 18 years, a history of tuberculosis, a positive diagnosis of tuberculosis infection in the meninges for at least 5 years, and willingness to sign an informed consent form as patients suffering from tuberculous meningitis (MTB) who would receive physiotherapy management using passive mobilization exercises, passive breathing exercises, and positioning. Data collection techniques were carried out by interviewing the patients' parents using a research instrument in the form of a clinical status sheet.

The data collection instruments used were a goniometer to measure ROM, a midline to measure thoracic cage expansion, a reflex hammer to examine reflexes, and a modified Ashworth scale (MAS) to measure spasticity. Data analysis was performed using descriptive qualitative methods, focusing on thoracic cage expansion and its specific examination.

The data collection procedure in this study was conducted systematically and sequentially through three stages. The data collection flow is presented in the following chart:

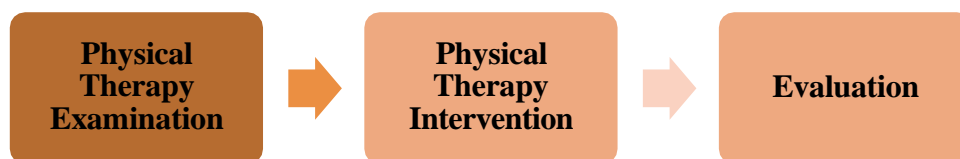

Figure 1. Data Collection Flowchart

In the initial stage, physiotherapy examinations were conducted on the research subjects, including anamnesis (main complaints, current medical history, past medical history, history of comorbidities, personal and family history); objective examinations (vital signs, static and dynamic inspection, percussion, palpation, auscultation); basic movement examination in the form of active movement, passive movement, isometric movement); cognitive, intrapersonal, and interpersonal examinations; specific examinations such as consciousness examination using the Glasgow Coma Scale (GCS), physiological and pathological reflex examinations, spasticity examinations, joint range of motion examinations, and chest expansion measurements.

The physiotherapy interventions provided to patients included positioning to prevent pressure ulcers and improve lung ventilation. Passive Breathing Exercises were performed to support respiratory function and prevent complications due to immobilization. Passive Mobilization Exercises were performed to maintain joint mobility and prevent stiffness. The physiotherapy intervention procedures are as follows: (1) Passive Breathing Exercise is given for 5 minutes without causing an increase in vital signs, with the patient in a supine lying position. The physiotherapist gently stretches all joints except the left knee, with each stretch performed 5x8 repetitions. Stop the exercise if there is an abnormal increase in vital signs. (2) Passive breathing exercise is performed with the patient in a supine lying position, then observe the patient's breathing pattern, then apply light pressure in the inferior direction when the patient exhales, do this for 5 minutes without causing an abnormal increase in vital signs. (3) Positioning is done by the physiotherapist preparing 3 pillows as the necessary tools. In the side lying position, tilt the patient to the right or left with pillows placed under the head, between the knees, and between the arms. In addition, position the lower arm slightly more forward than the upper arm. In the supine lying position, position the patient lying on their back with pillows placed under the head, in the popliteal fossa, and at the elbows.

The evaluation is carried out in stages, namely at the beginning of therapy or initial examination (T1), after the second session (T2), and after the third session (T3). The evaluation is carried out by measuring the range of joint motion using a goniometer, measuring spasticity using the Asworth scale, measuring the level of consciousness using the Glasgow Coma Scale (GCS), and measuring thoracic expansion using the midline.

RESULT AND DISCUSSION

Tuberculosis (TB) is a very serious global health issue caused by the bacterium *Mycobacterium tuberculosis*. This bacterium has lived alongside humans since ancient times. The disease spreads through inhalation of aerosol particles and primarily affects the lungs, causing coughing, fever, and chest discomfort. However, TB can also spread to other parts of the body, such as the lymph nodes, reproductive system, intestines, and bone and joint systems, through the blood and lymphatic systems.

The most dangerous and destructive form of tuberculosis is tuberculous meningitis (TBM). The inability of the immune system to fight TB can lead to its spread through the blood to distant parts of the body, including the brain and the membrane between the brain and the skull. The bacteria can multiply and cause local inflammation known as tuberculous meningitis. The characteristics and symptoms of TBM include changes in mental status, seizures, weakness in the cranial nerves, cerebral infarction, hydrocephalus, and tuberculoma, with increased basal meningeal signs as the main characteristic (Malik et al., 2025) (Lin, 2024).

Based on these clinical conditions, a comprehensive physiotherapy examination was conducted to assess the patient's health status and determine the appropriate intervention. The data obtained through physiotherapy examination of the patient included hetero anamnesis, objective examination, and specific examination. The objective examination included checking vital signs (ITV), IPPA (inspection, percussion, palpation, auscultation). The vital signs examination results were blood pressure 120/76 mmHg, pulse 108 beats per minute, respiration 32 breaths per minute, and temperature 36.9°C. The IPPA examination results were that the patient appeared unconscious with a nasogastric tube in place. In the upper extremities, the shoulders appeared symmetrical and slightly retracted, both arms were flexed, and the fingers were clenched. In the lower extremities, the knees were semi-flexed and the feet were dorsiflexed. The trunk tended to be hyperlordotic. There was minor skin peeling in the lower buttocks area. The patient's body appeared thin. Palpation revealed general hypertonicity in the AGA and AGB, and shortening of the tissue in the left knee. Auscultation revealed rhonchi in the chest. Specific examinations included consciousness assessment with GCS, physiological reflex examination, pathological reflex examination, spasticity examination, passive joint range of motion examination, and thoracic cage expansion examination.

Physical therapy interventions that can be provided for this condition include a combination of passive mobilization exercises, passive breathing exercises, and positioning. Passive mobilization exercises are performed because they can prevent problems such as joint stiffness and muscle spasms, which are often experienced by people who are bedridden. Physical therapy plays an important role in gradually restoring mobility and independence and expanding joint range of motion (ROM) (Pakhan & Raghumahanti, 2024b). This passive mobilization exercise is also combined with passive breathing exercises, or what some sources refer to as segmental breathing exercises. Segmental breathing exercises can increase sensory input and relearn normal movements by suppressing the diaphragmatic reflex. Hand contact on the intercostal area, as applied in the exercise, directly affects the diaphragm through the lower intercostal nerves. These nerves provide sensory fibers to the edges of the diaphragm as well as motor supply to the abdominal muscles. The tactile stimulation obtained during this exercise also has the potential to alter abdominal muscle tone, thereby affecting the mechanical interaction between the diaphragm and the abdominal wall muscles (Gaikwad & Shukla, 2024).

Passive mobilization exercises can have an immediate effect on local muscle function around the joint, supporting neuromuscular repair (Pfluegler et al., 2020). The final combination we implemented was the addition of positioning. This intervention is important because pressure ulcers can affect various areas of life, causing delays in recovery or treatment of the primary condition, and significantly reducing patient independence and freedom. A preventive and multidisciplinary approach to patient positioning and mobilization is essential to avoid complications, improve quality of life after discharge from the hospital, and reduce health deterioration. Pressure ulcers are one of the main complications of bedridden patients and their prevalence in the ICU is quite high. Patients requiring intensive care in the ICU often experience long-term negative effects, such as ICU-acquired weakness syndrome, as well as various neuropathies and myopathies. Patients' quality of life may also be negatively impacted cognitively, psychologically, relationally, and socially (Ippolito et al., 2022).

1. Passive Mobilization Exercise

The results of passive joint range of motion measurements at the beginning of the examination showed the same results from T1 to T3. Passive joint range of motion measurements were performed using a goniometer. These measurements were performed to determine the patient's joint range of motion. After intervention in the form of Passive Mobilization Exercise for 3 therapy sessions, the evaluation results showed no decrease or increase in the patient's joint range of motion. This was due to a limitation in this study, namely the lack of research time, especially in providing intervention to patients with MTB cases with general hypertonicity in the AGA and AGB and palpable tissue shortening in the left knee. The administration of intervention for three consecutive days was considered insufficient to produce an improvement in the passive range of motion in the patient. This intervention not only affects the results of joint range of motion evaluation, but is also useful in controlling patient spasticity. Passive Mobilization Exercise plays an important role in preventing an increase in spasticity and helping to reduce it due to prolonged immobility. This was proven in patient An. A.D.K. when measuring the level of spasticity, the results showed that there was no increase in spasticity in the joints. However, the measurement results also showed no decrease in spasticity levels. The objective of this intervention has not been achieved due to the limitations of this study, namely the lack of research time, particularly in providing intervention to patients with MTB who have muscle rigidity and contractures. Providing intervention for three consecutive days was considered insufficient to produce a decrease in spasticity in patients.

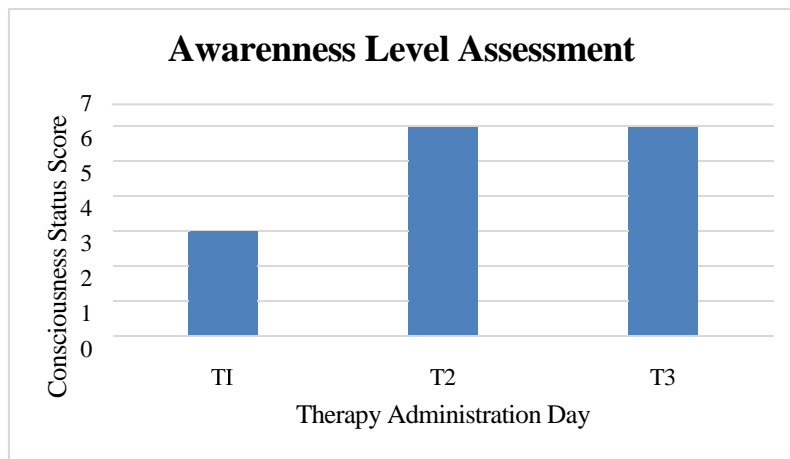


Figure 2. Table Evaluating Awareness Levels

The results of the third Passive Mobilization Exercise intervention were an evaluation of the level of consciousness measured using the Glasgow Coma Scale. The results showed that the patient experienced an increase in consciousness after the intervention, where initially the patient's consciousness was at a level of 3 and after the first and second therapies it increased to 6. This consciousness was obtained in the motor aspect, where when passive mobilization was performed on the side of the limb experiencing contracture, the patient responded by avoiding pain.

The Passive Mobilization Exercise procedure given to patients is as follows: the patient lies in a supine position, and the physiotherapist slowly stretches all joints except the left knee, with each stretch performed 5x8 repetitions. Stop the exercise if there is an increase in abnormal vital signs. This is in accordance with research conducted by Arjavi & Raghuvver (2024), which found that physiotherapy uses various methods to treat patients with motor disorders, including passive and active range of motion (ROM) exercises. This is important because it prevents complications such as

joint stiffness and muscle contractions, which often occur in individuals who have experienced immobilization. Physical therapy aids in the recovery of mobility and functional independence by gradually increasing range of motion (ROM) (Pakhan & Raghumahanti, 2024c).

2. *Passive Breathing Exercise*

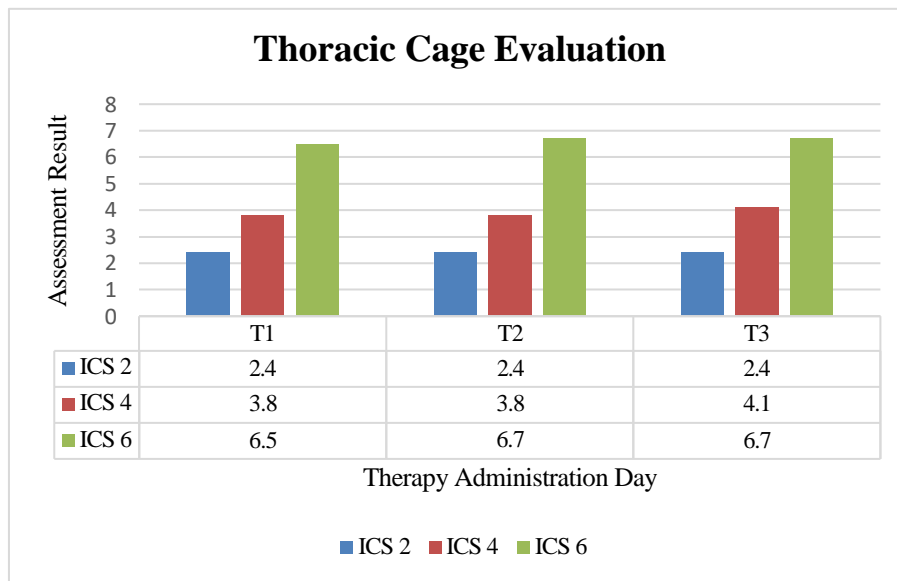


Figure 3. Evaluation Of The Thoracic Cage

Thoracic cage expansion measurements were taken using the midline at ICS 2, ICS 4, and ICS 6 during maximum inspiration and maximum expiration, then calculating the difference. The measurement results showed an increase in thoracic cage expansion at ICS 4 in the third meeting and at ICS 6 in the second and third meetings. At T2, the ICS 4 measurement was 3.8 cm, and at T3 it increased by 0.3 cm to 4.1 cm. Thoracic cage expansion also occurred at ICS 6, which was 6.5 cm at T1 and increased by 0.2 cm at T2 to 6.7 cm.

Passive breathing exercises are passive breathing techniques given to immobilized patients to support respiratory function and prevent complications resulting from immobilization. This is in line with research by Vikram Mohan et al. (2015), which found that passive breathing exercises can increase chest wall elevation and thus increase expansion to increase intra-thoracic lung volume, contributing to an increase in flow rate percentage. This can contribute to an increase in ventilation capacity, such as tidal volume, minute ventilation, and oxygen status. (Mohan et al., 2012).

CONCLUSION

The results of research obtained from the implementation of physiotherapy management in cases of tuberculous meningitis at the Haji East Java Regional General Hospital show that a combination of three physiotherapy interventions has an effect on improving patient condition, particularly in terms of increasing thoracic cage expansion and patient consciousness levels. These results were obtained after three physiotherapy interventions consisting of positioning, passive breathing exercises, and passive mobilization exercises. This has been proven to maintain joint range of motion, control spasticity, increase thoracic cage expansion, especially in maintaining basic functions, preventing complications, and helping to restore consciousness and respiratory capacity. Recommendations for further research include conducting long-term evaluations with more frequent interventions and monitoring the effects of physical therapy on motor function and the



patient's quality of life comprehensively. This research could also expand physical therapy interventions to optimize rehabilitation outcomes for patients with tuberculosis meningitis.

REFERENCES

- Aherrao, S., Harjpal, P., & Tikariha, A. (2024a). Extensive Physiotherapy Rehabilitation for Pulmonary Tuberculosis and Tuberculous Meningitis With Ventriculoperitoneal Shunting: A Case Report. *Cureus*. <https://doi.org/10.7759/cureus.70578>
- Aherrao, S., Harjpal, P., & Tikariha, A. (2024b). Extensive Physiotherapy Rehabilitation for Pulmonary Tuberculosis and Tuberculous Meningitis With Ventriculoperitoneal Shunting: A Case Report. *Cureus*. <https://doi.org/10.7759/cureus.70578>
- Catur Bintoro, A., Hadi, P., & Bagian Mikrobiologi Klinik UNISSULA Semarang, S. F. (2013). Gambaran Definitif Meningitis Tuberkulosa di RSUP dr. Kariadi Semarang Studi Deskriptif pada pasien dewasa dengan menggunakan real time PCR dengan target amplifikasi pada IS6110 Mycobacterium tuberculosis complex The Definitive Diagnosis of Tuberculous Meningitis (TBM) di RSUP dr. Kariadi Semarang Descriptive study in adult patients using IS6110-based PCR amplification for detecting Mycobacterium tuberculosis. In *Juli-Desember* (Vol. 5, Issue 2).
- Gaikwad, P. R., & Shukla, M. P. (2024). Effect of Segmental Expansion Exercises on Pulmonary Function in Patients with Upper Abdominal Surgery- A Randomized Controlled Trial. *Internet Journal of Allied Health Sciences & Practice*, 22(4), 1–10.
- Garrod, R., & Lasserson, T. (2007). Role of physiotherapy in the management of chronic lung diseases: An overview of systematic reviews. In *Respiratory Medicine* (Vol. 101, Issue 12, pp. 2429–2436). <https://doi.org/10.1016/j.rmed.2007.06.007>
- Global Tuberculosis Report 2021*. (2021). World Health Organization. *Global Tuberculosis report 2022*. (2022). <http://apps.who.int/bookorders>. *Global Tuberculosis Report 2023*. (2023). World Health Organization.
- Ippolito, M., Cortegiani, A., Biancofiore, G., Caiffa, S., Corcione, A., Giusti, G. D., Iozzo, P., Lucchini, A., Pelosi, P., Tomasoni, G., & Giarratano, A. (2022). The prevention of pressure injuries in the positioning and mobilization of patients in the ICU: a good clinical practice document by the Italian Society of Anesthesia, Analgesia, Resuscitation and Intensive Care (SIAARTI). *Journal of Anesthesia, Analgesia and Critical Care*, 2(1). <https://doi.org/10.1186/s44158-022-00035-w>
- Liao, Q., Zheng, Y., Wang, Y., Ye, L., Liu, X., Jiao, W., Liu, Y., Zhu, Y., Jia, J., Sun, L., Shen, A., & Wan, C. (2022). Effectiveness of Bacillus Calmette-Guérin vaccination against severe childhood tuberculosis in China: a case-based, multicenter retrospective study. *International Journal of Infectious Diseases*, 121, 113–119. <https://doi.org/10.1016/j.ijid.2022.04.023>
- Lin, F. (2024). Tuberculous meningitis diagnosis and treatment: classic approaches and high-throughput pathways. *Frontiers in Immunology*, 15(January), 1–9. <https://doi.org/10.3389/fimmu.2024.1543009>
- Malik, M. A., Kamran, A., Ahsan, D., Amjad, A., Moatter, S., Noor, A., Sohaib, A., Shaukat, M., Masood, W., Hasanain, M., & Mahmmod Fadelallah Eljack, M. (2025). Advances in management and treatment of tubercular meningitis – a narrative review. *Annals of Medicine & Surgery*, 87(6), 3673–3681. <https://doi.org/10.1097/ms9.0000000000003348>
- Manyelo, C. M., Solomons, R. S., Walzl, G., & Chegou, N. N. (2021). Tuberculous meningitis: Pathogenesis, immune responses, diagnostic challenges, and the potential of biomarker-based approaches. In *Journal of Clinical Microbiology* (Vol. 59, Issue 3). American Society for Microbiology. <https://doi.org/10.1128/JCM.01771-20>

- Mohan, V., Badlisyah, K., Aziz, K., Kamaruddin, K., Leonard, J. H., Das, S., Jagannathan, M. G., Alam, P., Program, P., Kebangsaan, U., Lumpur, K., La-, C., Teknologi, U., & Campus, P. A. (2012). Effect of Intercostal Stretch on Pulmonary Function. *EXCLI Journal*, 284–290.
- Pakhan, A. A., & Raghumahanti, R. (2024a). Targeted Six-Week Intensive Physiotherapy for a Case of Tuberculous Meningitis With a Syndrome of Inappropriate Antidiuretic Hormone Secretion. *Cureus*. <https://doi.org/10.7759/cureus.55214>
- Pakhan, A. A., & Raghumahanti, R. (2024b). Targeted Six-Week Intensive Physiotherapy for a Case of Tuberculous Meningitis With a Syndrome of Inappropriate Antidiuretic Hormone Secretion. *Cureus*, 16(2), 1–9. <https://doi.org/10.7759/cureus.55214>
- Pakhan, A. A., & Raghumahanti, R. (2024c). Targeted Six-Week Intensive Physiotherapy for a Case of Tuberculous Meningitis With a Syndrome of Inappropriate Antidiuretic Hormone Secretion. *Cureus, February*. <https://doi.org/10.7759/cureus.55214>
- Pflugler, G., Kasper, J., & Luedtke, K. (2020). The immediate effects of passive joint mobilisation on local muscle function. A systematic review of the literature. *Musculoskeletal Science and Practice*, 45. <https://doi.org/10.1016/j.msksp.2019.102106>
- Poety Elberta Husna Nixon. (2025). HUBUNGAN STATUS IMUNISASI BCG DENGAN MORTALITAS DAN DERAJAT SEVERITAS MENINGITIS TUBERKULOSIS ANAK DI RSUP DR. M. DJAMIL PADANG PERIODE 2018 – 2021. *SINERGI*.
- Thuong, N. T. T., Heemskerk, D., Tram, T. T. B., Thao, L. T. P., Ramakrishnan, L., Ha, V. T. N.,
- Bang, N. D., Chau, T. T. H., Lan, N. H., Caws, M., Dunstan, S. J., Chau, N. V. V., Wolbers, M., Mai, N. T. H., & Thwaites, G. E. (2017). Leukotriene A4 hydrolase genotype and HIV infection influence intracerebral inflammation and survival from tuberculous meningitis. *Journal of Infectious Diseases*, 215(7), 1020–1028. <https://doi.org/10.1093/infdis/jix050>